

The role of immunohistochemistry for ERCC1 in determining therapeutic response in non-small cell lung carcinomas:

March 2007

by Bahram Robert Oliai, M.D.

The ability to target specific therapeutic agents to those patients who will derive the greatest benefit (so-called “personalized medicine”) is one of the new frontiers of medical therapy. As we uncover the molecular mechanisms which drive various neoplastic disorders, what were once daunting challenges are becoming new opportunities to treat our patients with specific, highly effective, life-saving medicines. One only need look to the success stories of STI-571 in the treatment of chronic myelogenous leukemia (CML) and gastrointestinal stromal tumor (GIST), and Trastuzumab in breast cancer as examples of this new approach. However, since these drugs can be very expensive and associated with a significant risk of toxicity, optimal use of these agents requires that we seek methods to identify those patients who will truly benefit, while sparing those likely to experience little or no beneficial response.

In this month’s FOCUS we examine the possibly revolutionary new immunoperoxidase stain for ERCC1 (now available to ProPath clients) and explore its utility in helping guide therapeutic decisions in non-small cell lung cancer.

Lung cancer (of which more than 75% are classified as non-small cell carcinomas) is the leading cause of cancer-related death in most industrialized nations. Unfortunately, up to 33% of patients with completely resected stage IA tumors die of disease within five years. Given this grim statistic, and the demonstrated survival benefit of chemotherapy after complete resection, many patients are treated post-operatively with platinum-based regimens. While certainly effective, platinum (cisplatin, carboplatin, oxaloplatin) is not an innocuous drug and is associated with myriad toxic side effects. Specifically nephropathy, neuropathy (including deafness), gas-

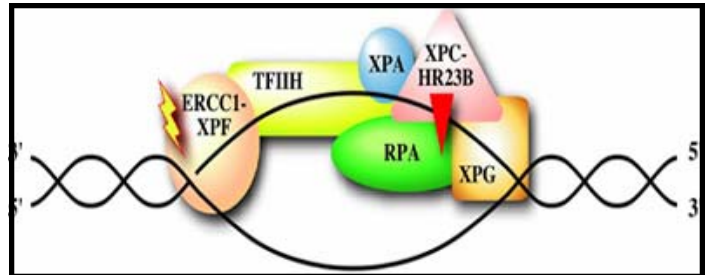


Figure 1: Diagram showing the ERCC1-XPF complex incising the 5' side of damaged DNA. (from Google)

trointestinal disturbance, and myelosuppression are some of the more common side effects, which at times may be irreversible. Therefore, adjuvant platinum therapy should ideally only be administered to those that can benefit, while avoiding potential toxicities in those that will not respond. This is precisely where ERCC1 immunostains have been found to be useful.

ERCC1 stands for "Excision Repair Cross-Complementation Group 1" enzyme. It is essential for life, as it is one of the proteins involved in DNA repair. ERCC1 functions by excising the 5' end of damaged DNA (Figure 1) and may well represent the rate limiting step in the in this process. By now you may be asking yourself "What relevance does all this have to lung cancer and chemotherapy?"

Several studies have shown that in the setting of treatment with a platinum-based regimen, those patients with tumors expressing low levels of ERCC1 mRNA (assessed by RT PCR) survive significantly longer than those expressing high levels. In essence the tumors that expressed higher levels of ERCC1 showed resistance to platinum-based therapy! Intuitively, this seems logical, as tumors with higher levels of ERCC1 would be better able to counteract the

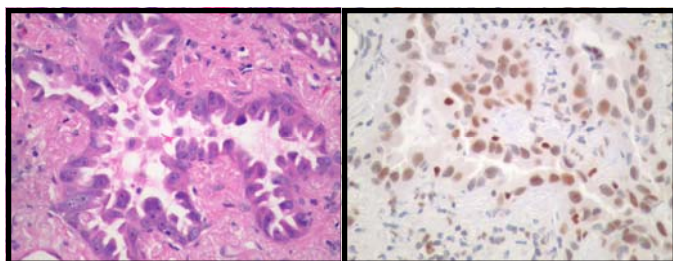


Figure 2: H&E (left) and ERCC1 stain (right) on an ERCC1 positive pulmonary adenocarcinoma. Note strong and diffuse nuclear staining for ERCC1.

DNA damage induced by cisplatin, which is critical to the anti-tumor effects of the drug.

In the September 2006 issue of *The New England Journal of Medicine*, Olausen et al. described the use of immunohistochemistry to determine the ERCC1 status of lung tumors from paraffin embedded, surgical material. In this study, an “ERCC1 positive tumor” was defined as one that showed moderate nuclear staining in >50% of neoplastic cells or strong nuclear staining in >10% of neoplastic cells (Figure 2). Tumors with lesser staining were interpreted as “ERCC negative” (Figure 3). In their study of 761 non-small cell lung carcinomas, ERCC1 negative tumors that were completely resected were associated with a prolonged survival benefit from cisplatin-based adjuvant therapy, while those with ERCC1 positive tumors essentially received no benefit. However, in the group of patients who did not receive adjuvant chemotherapy, those with ERCC1 positive tumors survived longer than those with ERCC1 negative tumors, so it seems that ERCC1 negativity may be a “double-edged sword” so to speak.

At ProPath we now have the same ERCC1 antibody used in Olausen’s paper, have titered it in our lab, and have used it clinically with success. In most cases results can be made available to referring phy-

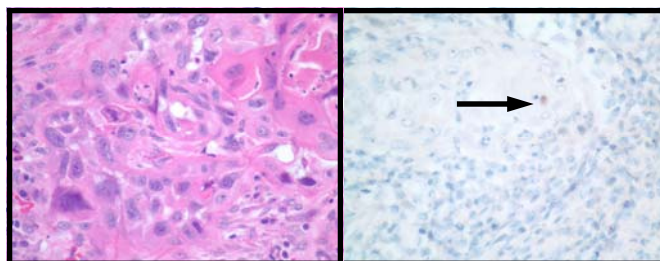


Figure 3: ERCC1 negative pulmonary squamous carcinoma. The neoplastic nuclei are negative for ERCC1 (right), while an admixed inflammatory cell is positive (normal, arrow).

sicians in less than 24 hours. At ProPath the rapid and accurate incorporation of assays such as this one into our clinical practice illustrates our commitment to help each patient find their unique road to recovery.

Acknowledgments:

We would like to thank Dr. Pam Jensen of the Presbyterian Hospital in Dallas, Texas for calling our attention to this most interesting new immunohistochemical stain.

References:

1. Olausen KA, Dunant A, Fouret P, et al. DNA Repair by ERCC1 in Non-Small-Cell Lung Cancer and Cisplatin-Based Adjuvant Chemotherapy. *The New England Journal of Medicine* 2006; 355: 983-91.
2. Lord RVN, Brabender J, Gandera D, et al. Low ERCC1 Expression Correlates with Prolonged Survival in Non-Small Cell Lung Cancer. *Clinical Cancer Research* 2002; 8: 2286-2291.
3. Reed E. ERCC1 Measurements in Clinical Oncology (Editorial). *The New England Journal of Medicine* 2006; 355: 1054-1055.

Bahram Robert Oliai M.D.



Dr. Oliai is the newest addition to ProPath’s IHC lab and Consultation service. Dr. Oliai is board certified in Anatomic and Clinical Pathology and Cytopathology by the American Board of Pathology. After graduating from the University of Illinois College of Medicine, Dr. Oliai completed an AP/CP residency and Surgical Pathology fellowship at The Johns Hopkins Hospital. He then completed a second fellowship at the Memorial Sloan Kettering Cancer Center in Cytopathology. Before joining the IHC lab at ProPath, he spent two years in private practice in Chicago and did additional subspecialty training in Urologic Pathology at The Johns Hopkins Hospital. For direct inquiries to Dr. Oliai, contact him at Robert.Oliai@propathlab.com

PROPATH

8267 Elmbrook Dr, Ste 100
Dallas, Texas 75247-4009
(214) 638-2000
(800) 258-1253
www.propathlab.com

Of all the molecular alterations that may have predictive value in non-small cell lung cancer (NSCLC), testing for EGFR mutations is usually the first step in determining course of adjuvant therapy....¹ Azuma K et al (2009) Expression of ERCC1 and class III beta-tubulin in non-small cell lung cancer patients treated with carboplatin and paclitaxel. *Lung Cancer* 64(3):326-333 PubMedGoogle Scholar. 111. Lee HW et al (2009) Expression of excision repair cross-complementation group 1 protein predicts poor outcome in advanced non-small cell lung cancer patients treated with platinum-based doublet chemotherapy. *Lung Cancer* 65(3):377-382 PubMedGoogle Scholar. 112. Lung cancer (of which more than 75% are classified as non-small cell carcinomas) is the leading cause of cancer-related death in most industrialized nations. Unfortunately, up to 33% of patients with completely resected stage IA tumors die of disease within five years. Given this grim statistic, and the demonstrated survival benefit of chemotherapy after complete resection, many patients are treated postoperatively with platinum-based regimens.² DNA Repair by ERCC1 in Non-Small-Cell Lung Cancer and Cisplatin-Based Adjuvant Chemotherapy. *The New England Journal of Medicine* 2006; 355: 983-91. 2. Lord RVN, Brabender J, Gandra D, et al. Low ERCC1 Expression Correlates with Prolonged Survival in Non-Small Cell Lung Cancer. *Clinical Cancer Research* 2002; 8: 2286-2291. Request PDF | Automated ERCC1 Immunohistochemistry in Non-small Cell Lung Cancer: Comparison of anti-ERCC1 Antibodies 8F1, D-10, and FL-297 | The excision repair cross-complementation group 1 (ERCC1) protein is the key enzyme of the nucleotide excision repair (NER) pathway and thus a | Find, read and cite all the research you need on ResearchGate.³ We aimed for evaluating different anti-ERCC1 antibodies on formalin-fixed tumor tissue of non-small cell lung cancer patients by automated immunohistochemistry (IHC). ERCC1 protein expression was assessed on a tissue microarray of 491 NSCLC's using 2 monoclonal mouse (Mab 8F1, Mab D-10) and 1 polyclonal rabbit (Rab FL-297) antibody.